

# First Case of Mesenteric Extraosseous Osteosarcoma in Australia

Xiang Salim\*, David Paton, Anton Lambers and Richard Carey Smith

Sir Charles Gairdner Hospital, Perth, WA, Australia

## Abstract

An Extraosseous Osteosarcoma (EOS) arising in mesentery is exceedingly rare with only six previous cases documented in English literature worldwide. This manuscript describes the clinical, radiological and histological features of the first known case of mesenteric EOS in Australia. The collation of additional cases will help ameliorate our understanding of its clinical course and guide appropriate management, planning and prognostication.

**Keywords:** Osteosarcoma; Extraosseous; Mesenteric; Histopathology; Radiology; Orthopaedic

## Introduction

Osteosarcomas are rare aggressive malignant neoplasms of mesenchymal origin that exhibits osteoblastic differentiation. Osteosarcomas are associated with a poor prognosis despite aggressive treatment. An Extraosseous Osteosarcoma (EOS) is a further rare occurrence, whereby the lesion in question arises in soft tissue unattached to bone or periosteum. EOS usually arise in the limbs and an EOS arising in mesentery is exceedingly rare with only six previous cases documented in English literature worldwide. Due to the low number of documented cases, there is a poor understanding of the clinical course of the disease and no recommended management exists.

## Clinical Record

A 63-year-old male presented to emergency department with a one-month history of worsening abdominal pain and loose stools. This was on a background of prostatic adenocarcinoma treated six years prior with prostatectomy and adjuvant radiotherapy. Examination revealed left iliac fossa tenderness, guarding, without a palpable mass. A 13×7×11 cm mesenteric mass was demonstrated on computed tomography, with internal derangement and a central hypodense area suggestive of necrosis. In direct continuity was a heavily calcified nidus, measuring 5.5 cm (Figure 1).

Emergency explorative laparotomy was performed, and an en bloc resection of the tumour and three adherent loops of small bowel was performed. Post-operative recovery was uneventful.

The resected tumour measured 15×9×9 cm and was adherent to the three segments of small bowel. The mass was well demarcated with a smooth, nodular external surface which appeared to centre on the mesentery. Sectioning demonstrated a lobulated, white fibrous cut surface with extensive calcification, haemorrhage and necrosis (Figure 2).

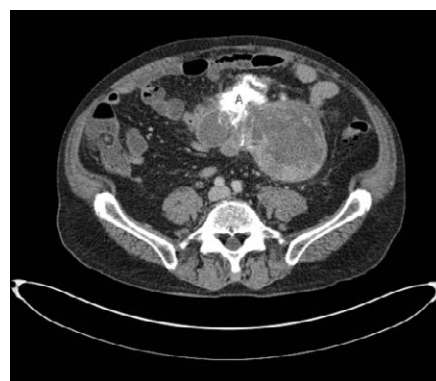Histological sections confirmed a well-circumscribed mesenteric-based tumour which extended focally into the muscularis propria of the small bowel, but did not involve the submucosa or mucosa. The tumour was composed of cellular nodules of plump spindle to epithelioid cells with a peppering of reactive osteoclastic type giant cells (Figure 3). Mitotic activity was brisk, measuring up to 39/10 high power fields. Cell-rich areas were interspersed with geographical areas of necrosis and extensive lace-work of calcified osteoid. The malignant cells were intimately associated with the osteoid and incorporated into the formed bone. Despite extensive sampling no areas of heterologous or lipomatous differentiation were identified.

By immunohistochemistry the tumour cells stained positively for CDK4 and weakly for MDM2. Fluorescent in-situ hybridisation (FISH) analysis confirmed amplification of both the MDM2 and the CDK4 genes. A diagnosis of dedifferentiated EOS was therefore made.

A post-operative PET scan at one month revealed two intraperitoneal soft tissue masses. A subsequent CT abdomen and pelvis confirmed the presence of these two calcified lesions; one in the mesentery (37×21 mm) and a second in the pelvis (15×18 mm). Chemotherapy with adriamycin was initiated. Follow-up CT at 6 months post operation showed interval increase in size along with the emergence of several new calcific structures. Following further clinical deterioration, palliation was initiated and the patient died from progressive disease 18 months following initial presentation.

## Discussion

Extraskeletal Osteosarcomas (EOSs) are exceedingly rare,



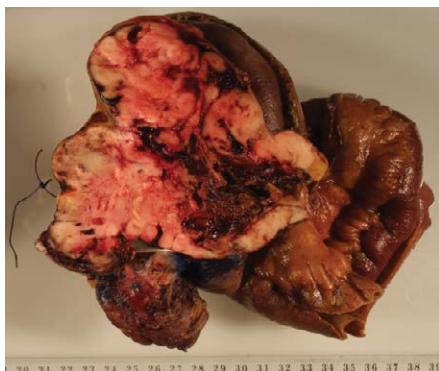
**Figure 1:** Computed tomography axial slice at level of mass showing heavily calcified nidus (A), measuring 5.5 cm with fibrotic reaction and extensive spiculation extending into the mesentery.

**\*Corresponding author:** Xiang Salim, 55 Viewway Nedlands, 6009, Perth, WA, Australia, Tel: +61 466 724278; E-mail: [xiangsalim1@gmail.com](mailto:xiangsalim1@gmail.com)

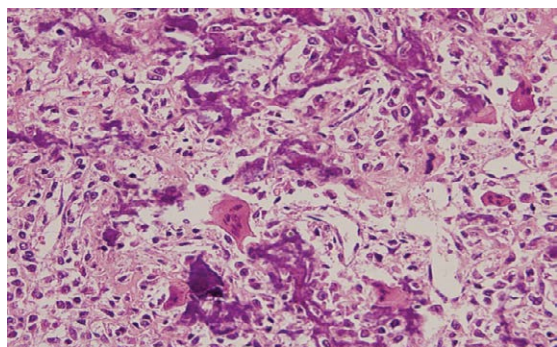
**Received** February 25, 2016; **Accepted** March 10, 2016; **Published** March 16, 2016

**Citation:** Salim X, Paton D, Lambers A, Smith RC (2016) First Case of Mesenteric Extraosseous Osteosarcoma in Australia. J Oncol Med & Pract 1: 104. doi:[10.4172/jomp.1000104](https://doi.org/10.4172/jomp.1000104)

**Copyright:** © 2016 Salim X, et al. This is an open-access article distributed under the terms of the Creative Commons Attribution License, which permits unrestricted use, distribution, and reproduction in any medium, provided the original author and source are credited.



**Figure 2:** Resected tumour sectioned demonstrating a lobulated, white fibrous cut surface with extensive calcification, haemorrhage and necrosis.



**Figure 3:** Microscopically (40X) the tumour was composed predominantly of nodules of epithelioid to spindle-shaped cells with pale eosinophilic cytoplasm showing mixed growth patterns with interspersed lace-like calcified osteoid and osteoclast-like giant cells.

accounting for 4% of all osteosarcomas and less than 1% of all sarcomas [1-4]. The criteria for the diagnosis of an EOS by Allan et al. are: uniform morphological pattern of sarcomatous tissue that excludes the possibility of malignant mesenchymoma, the production of malignant osteoid/bone by the sarcomatous tissue, and the definite exclusion of an osseous origin [1]. EOS usually occur in the thigh (47%), upper limb (20%) or retroperitoneum (17%) and are rarely found in visceral organs (3). There are only six previous cases of primary mesentery EOS in English literature, with none in Australia thus far [4-7].

The radiological appearance of EOS on CT is typically a calcified mass with areas of soft tissue attenuation [2]. MRI shows a non-specific intermediate signal intensity on T1 and high signal intensity on T2 [8]. PET scan shows increased uptake of the radiotracer by the osteosarcoma.

Radiological features are seldom conclusive without histological confirmation and the differential diagnosis includes various benign and malignant soft tissue lesions. Benign processes for consideration include myositis ossificans (heterotopic mesenteric ossification does exist), giant cell tumour, haemangi endothelioma, calcified haematoma or calcified lymph nodes. Malignant entities include a dedifferentiated liposarcoma with osseous or cartilaginous elements (when a fatty component is present) or malignant fibrous histiocytoma (MFH) [2,3].

Histologically, EOSs are characterized by atypical spindle cells and

epithelioid mesenchymal cells, producing abnormal lace-like osteoid along with nuclei displaying high grade pleomorphism with frequent mitoses including abnormal mitotic figures [6].

In this case the histological appearances were of high-grade osteosarcoma. FISH analysis confirmed amplification of the MDM2 and CDK4 genes. Such amplifications are known to occur in both de-differentiated liposarcoma and de-differentiated osteosarcoma [9]. Of note, these amplifications have been demonstrated in de-differentiated EOS [10]. Although osteosarcomatous differentiation is a described phenomenon in de-differentiated liposarcoma, extensive sampling in our case did not identify a lipomatous component, effectively excluding this diagnosis.

Interestingly, appendicular EOS appear to behave differently to osseous osteosarcoma [11,12]. EOS treatment in limbs is usually wide resection or amputation with adjuvant chemotherapy and radiation therapy [11,12]. Tumour size less than 5 cm appears to be an important prognostic factor for appendicular EOS [1]. Despite aggressive treatment, local recurrence occurs in one third of patients and there is a high risk of metastasis [1-3]. Fan et al. [11] found that tumour size was the strongest predictor of local recurrence. They also found radiation and chemotherapy (doxorubicin/ifosfamide) to be associated with lower recurrence, but not disease-specific survival in multivariate analysis [11]. Ahmad et al. also found multimodal therapy to be preferable with doxorubicin-based systemic therapies having a low response rate [12]. Overall the prognosis with EOS is poor with a 60–70% 5 year mortality despite current treatment [1-3]. Similar to EOS behaving differently to osseous osteosarcoma, it is also possible that mesenteric EOS may behave differently to both these entities and only through comparison of further cases will we be able to better understand its clinical course.

This is the first documented Australian case of mesenteric EOS, with only six previous cases described in English literature worldwide. Given the rarity of mesenteric EOS, its biological behaviour is yet to be fully understood and a promising therapeutic regimen does not exist. However, as with any oncology patient a multidisciplinary team approach including surgical, radiation and medical oncology as well as allied health should be the foundation of care. The collation of additional cases will advance our understanding of its clinical course and guide the rationale for appropriate management, planning and prognostic estimation.

## References

1. Allan CJ, Solle EH (1971) Osteogenic sarcoma of the somatic soft tissues. Clinicopathologic study of 26 cases and review of literature. *Cancer* 27: 1121-1133.
2. Bane BL, Evans HL, Ro JY, Carrasco CH, Grignon DJ, et al. (1990) Extraskelatal osteosarcoma: a clinicopathologic review of 26 cases. *Cancer* 66: 2762-2770.
3. Chung EB, Enzinger FM (1987) Extraskelatal osteosarcoma. *Cancer* 60: 1132-1142.
4. Fine G, Stout AP (1956) Osteogenic sarcoma of the extraskelatal soft tissues. *Cancer* 9: 1027-1043.
5. Choundur HN, Munk PL, Nielson TO, Ryan AG (2005) Primary mesenteric extraskelatal osteosarcoma in the pelvic cavity. *Skeletal Radiology* 34: 649-652.
6. Hussain MI, Al-Akeely MH, Alam MK, Jasser NA (2011) Extraskelatal osteosarcoma, telangiectatic variant arising from the small bowel mesentery. *Saudi Medical Journal* 32: 958-961.
7. Ahmed SA, Mohammed U, Garba ES, Calvin B, Shehu MS (2013) Primary mesenteric extraskelatal osteosarcoma. *Nigerian Journal of Basic Clinical Sciences* 10: 95-97.

8. Varma DGK, Ayala AG, Guo SQ, Mouloupoulos LA, Kim EE, et al. (1993) MRI of extraskeletal osteosarcoma. Journal of Computer Assisted Tomography 17: 414-417.
9. Yoshida A, Ushiku T, Motoi T, Beppu Y, Tsuda H, et al. (2012) MDM2 and CDK4 Immunohistochemical Coexpression in High-grade Osteosarcoma: Correlation With a Dedifferentiated Subtype. Am J Surg Pathol 36: 423-431.
10. von Baer A, Ehrhardt A, Baumhoer D, Mayer-Steinacker R, Fend F, et al. (2014) Immunohistochemical and FISH analysis of MDM2 and CDK4 in a dedifferentiated extraskeletal osteosarcoma arising in the vastus lateralis muscle: Differential diagnosis and diagnostic algorithm. Pathology Research & Practice 210: 698-703.
11. Fan Z, Patel S, Lewis VO, Guadañolo BA, Lin PP (2015) Should High-grade Extrasosseous Osteosarcoma Be Treated With Multimodality Therapy Like Other Soft Tissue Sarcomas. Clin Orthop Relat Res 473: 3604-3611.
12. Ahmad SA, Patel SR, Ballo MT, Baker TP, Yasko AW, et al. (2002) Extrasosseous osteosarcoma: response to treatment and long-term outcome. J Clin Oncol 20: 521-527.

**Citation:** Salim X, Paton D, Lambers A, Smith RC (2016) First Case of Mesenteric Extraosseous Osteosarcoma in Australia. J Oncol Med & Pract 1: 104. doi:[10.4172/jomp.1000104](https://doi.org/10.4172/jomp.1000104)

#### OMICS International: Publication Benefits & Features

##### Unique features:

- Increased global visibility of articles through worldwide distribution and indexing
- Showcasing recent research output in a timely and updated manner
- Special issues on the current trends of scientific research

##### Special features:

- 700 Open Access Journals
- 50,000 Editorial team
- Rapid review process
- Quality and quick editorial, review and publication processing
- Indexing at PubMed (partial), Scopus, EBSCO, Index Copernicus, Google Scholar etc.
- Sharing Option: Social Networking Enabled
- Authors, Reviewers and Editors rewarded with online Scientific Credits
- Better discount for your subsequent articles

Submit your manuscript at: <http://www.omicsonline.org/submission>